

# **Ear Erythema after using topical Minoxidil for Androgenetic Alopecia**

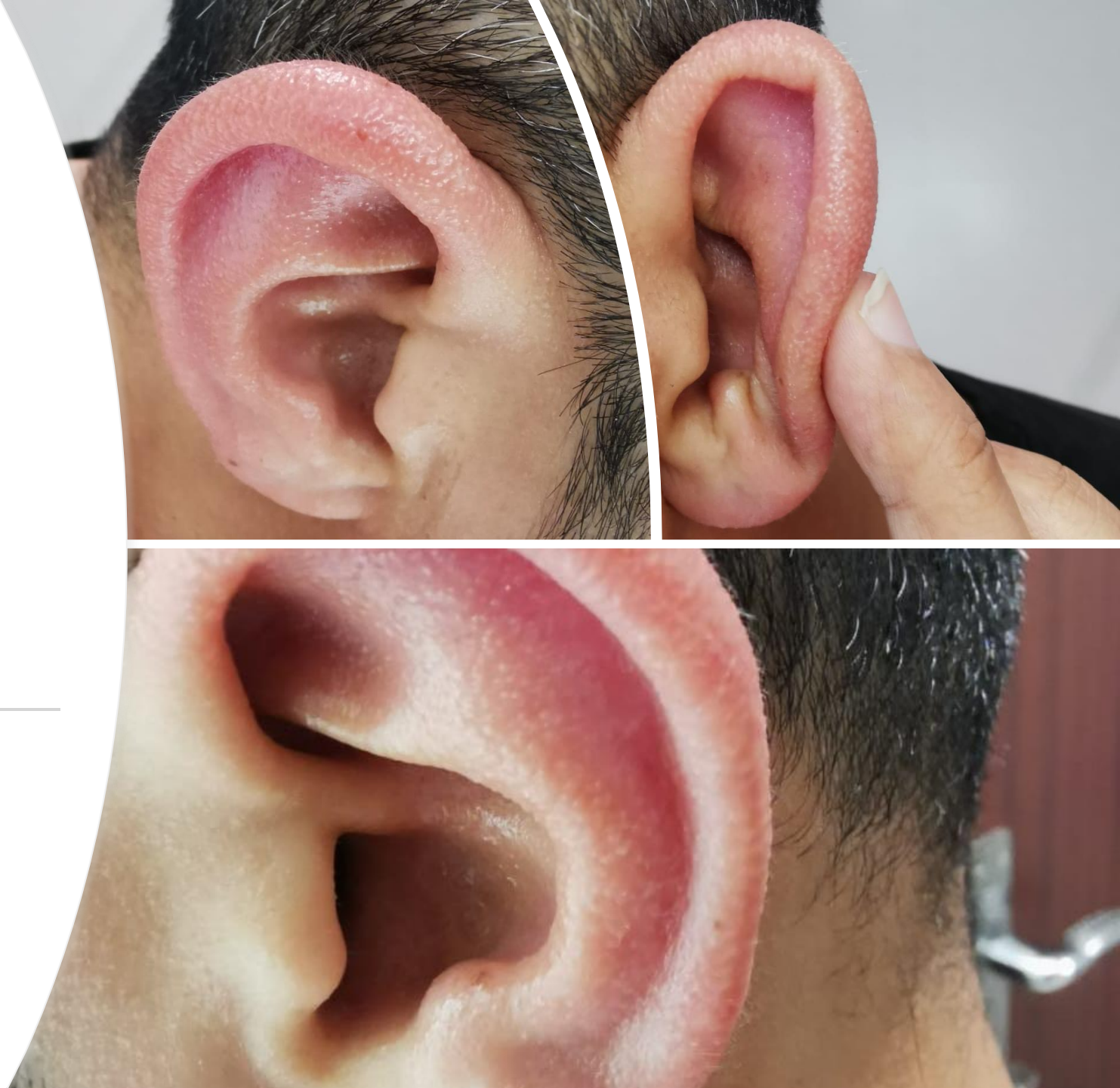---

Dr. Abdurrahman Almurayshid

Department of Medicine, College of Medicine, Prince Sattam Bin  
Abdulaziz University, Al-Kharj City, 11942, Saudi Arabia.

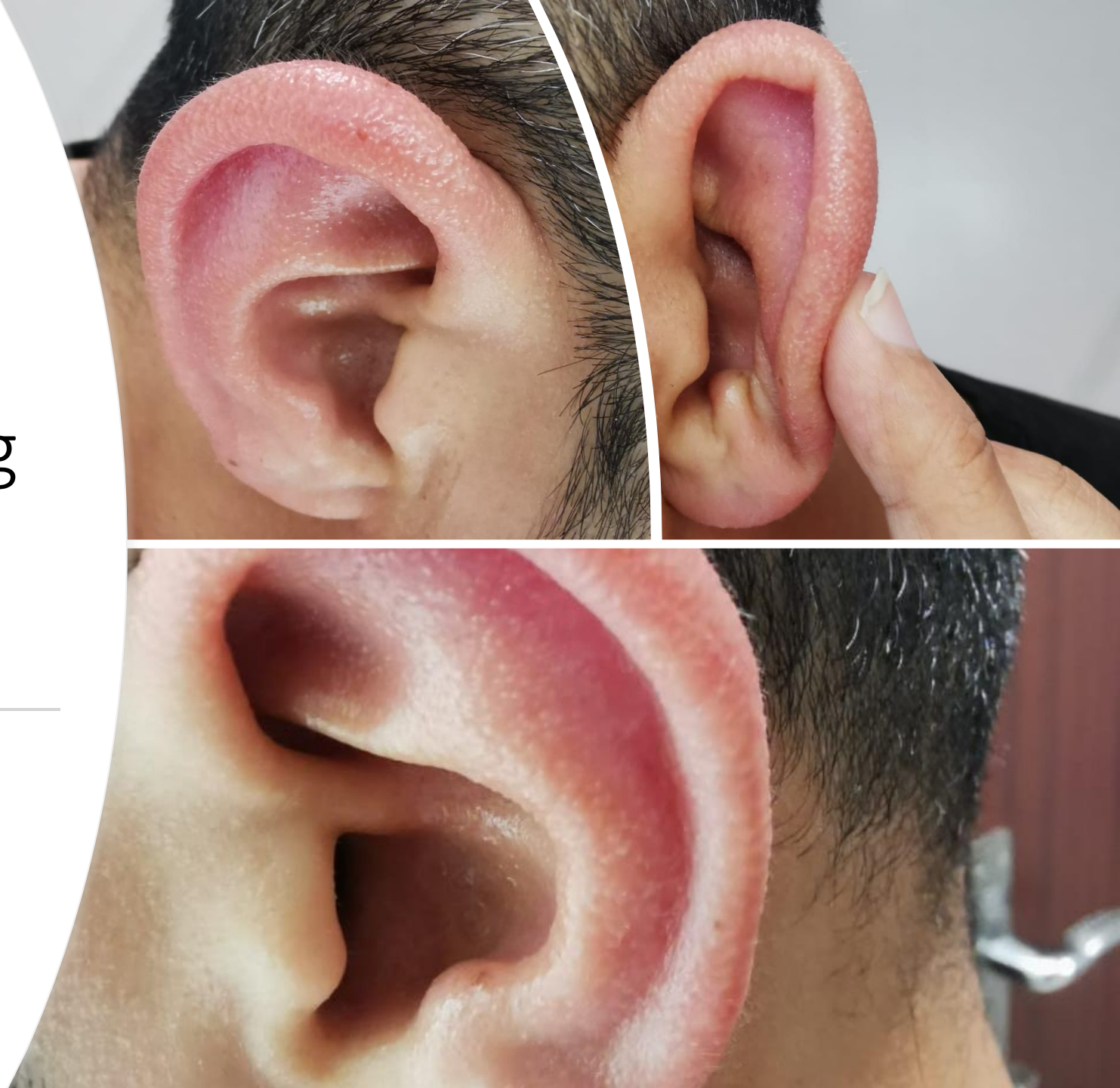Case of 34 years old male using minoxidil for the treatment of Androgenetic Alopecia.

---



He developed  
Erythema and swelling  
three months after  
starting minoxidil.

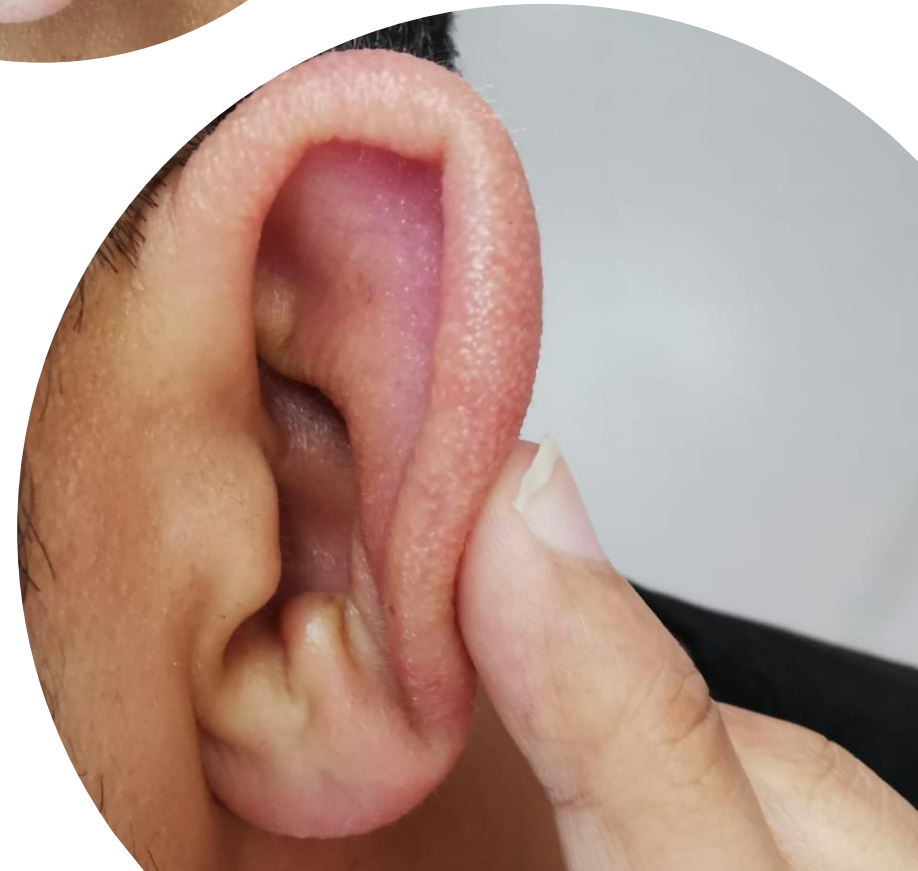
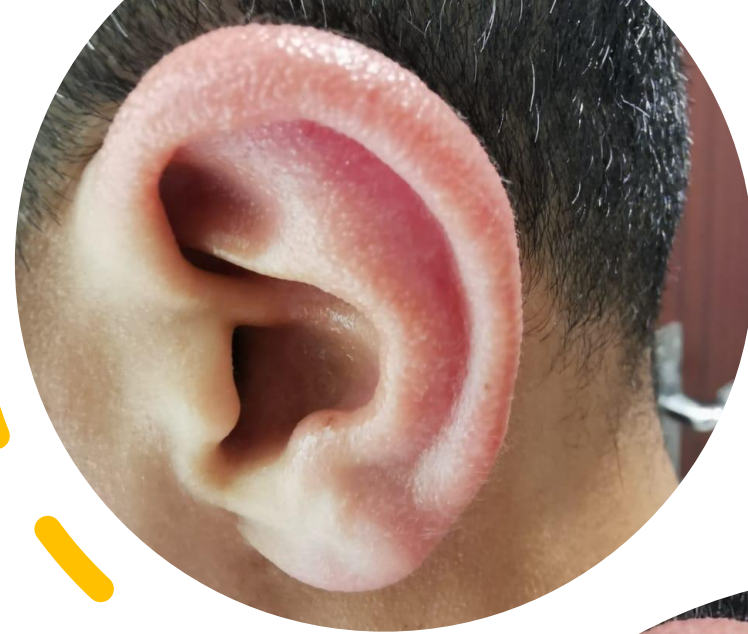---





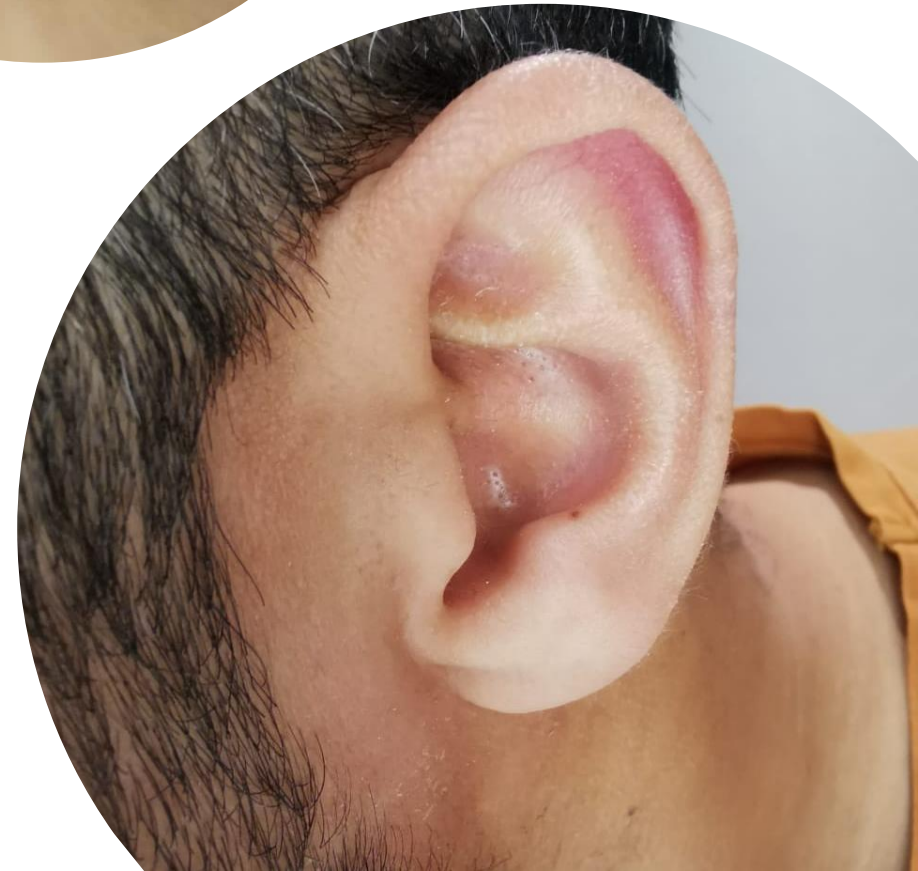
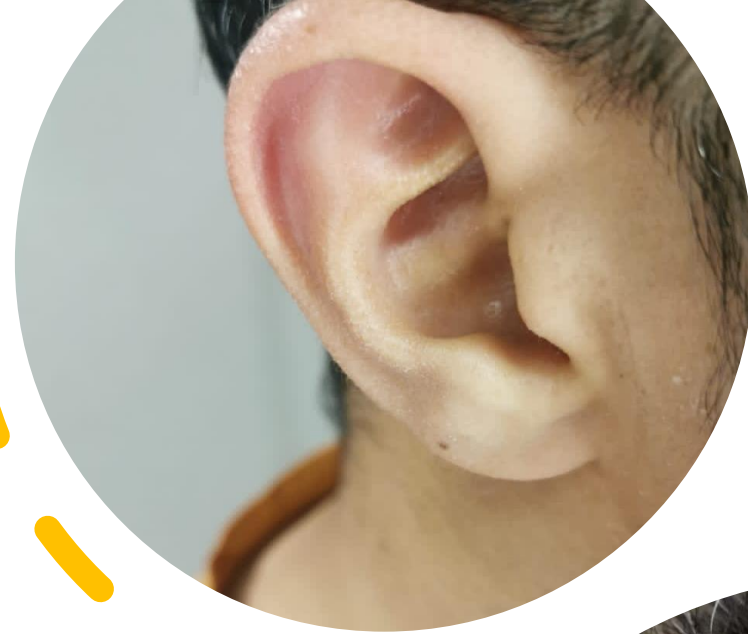What is the possible cause of his problem?

- He has used minoxidil spray for the scalp; however, he admits that sometimes he sprays near the ears.



# Treatment

- Moisturizers
- Use the minoxidil correctly
- Resolved within two weeks



# Literature review

---

- Vasodilatation of the vessels can be the cause.(1)
- Contact dermatitis might also be another possibility.(2)
- Only one case report for redness and flushing of the face and ears in a young child after accidental ingestion of topical minoxidil.(3)

# Conclusion

---

- Topical Minoxidil might induce flushing and redness of the ear.
- Proper application of the treatment will prevent this rare side effect.

# References

1. Toriumi DM, Konior RJ, Berktold RE. Severe Hypertrichosis of the External Ear Canal During Minoxidil Therapy. *Arch Otolaryngol Head Neck Surg*. 1988;114(8):918–919. doi:10.1001/archotol.1988.01860200102029
2. Degreef H, Hendrickx I, Doms-Goossens A. Allergic contact dermatitis to minoxidil. *Contact Dermatitis*. 1985 Sep;13(3):194-5. doi: 10.1111/j.1600-0536.1985.tb02542.x. PMID: 2932293.
3. Aprahamian A, Escoda S, Patteau G, Merckx A, Chéron G. Intoxication par le minoxidil, principe actif d'une lotion capillaire. À propos d'un cas [Minoxidil intoxication, the pharmacological agent of a hair lotion]. *Arch Pediatr*. 2011 Dec;18(12):1302-4. French. doi: 10.1016/j.arcped.2011.08.031. Epub 2011 Oct 15. PMID: 22001642.



# Dr. Abdurrahman Almurayshid

Contact ;

[almurayshid@gmail.com](mailto:almurayshid@gmail.com)

