

# Genital Harmonization:

A clinical experience with a combined

approach

Bulent Cihantimur MD- Plastic Surgeon  
Estetik International-Istanbul-Turkey

The background of the slide features a light blue-grey gradient with silhouettes of dried, pressed plant leaves in shades of brown and tan. A large white rectangular box is centered on the page, containing a single paragraph of text.

Although, several surgical techniques have been defined for the genital aesthetic operations in the literature, ideal appearance of vulva or the standards regarding the ratio of structures to each other remained undefined.



# The study

We aim to provide data on our 7 year clinical experience on female genital aesthetic operations in terms of achievement **of ideal size and appearance of vulva and the ratio of vulvar structures** without losing the functionality of the organ.

# Methods

---

2013 - 2020

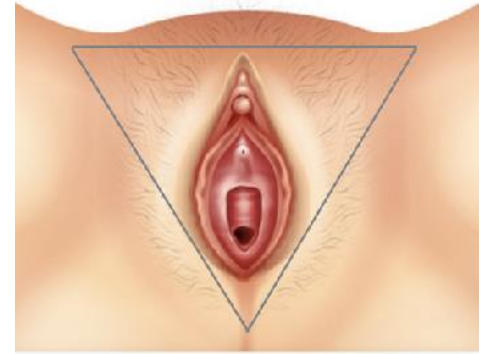- 430 patients had genital aesthetic operations (labiaplasty, clitoral hoodoplasty, labium fat filling)
- Fat Juice (SVF + fat extract) was injected to the G point, vaginal canal and skin to improve sensibility and enhance skin quality
- Genital area measurements were performed using digital photographs taken before and 3 months after operations



# Methods

---

## THE B TRIANGLE

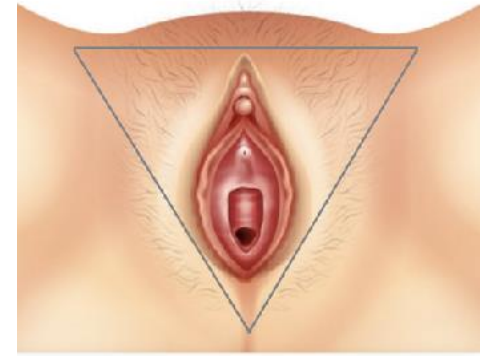

- In the TRIANGLE B view, the pubis forms the base of the triangle. The inguinal canals form the sides of the isosceles triangle. The pudendal cleft should terminate at an angle of 90 degrees to the base of the triangle, and also, the termination line should merge with the linea alba, which descends from the umbilicus in the vertical axis, at an angle of 180 degrees. The ratio of the vertical length of the pudendal cleft to the distance from its end to the base of the triangle should be between  $\frac{1}{2}$  and  $\frac{1}{3}$ . The labium majus should be at equal distance and equal height to the pudendal cleft as a reference point.

# Methods

---

## THE B TRIANGLE



This symmetry should be achieved in terms of width, height and volume by the application of nanofat fat grafts to the labium majus and pubic region. While injecting the fat graft, it should be ensured that the clitoris and clitoral hood are not visible in the standing upright position when looking straight ahead and remain hidden within the pudendal cleft. We also perform clitoral hoodoplasty to achieve this appearance if necessary.

# Methods

---

## SYMMETRY AND PROPORTIONS

- Symmetry should be achieved in terms of width, height and volume by the application of fat grafts to the labium majus and pubic region.
- The clitoris and clitoral hood should not be visible in the standing upright position and remain hidden within the pudendal cleft. We also performed clitoral hoodoplasty to achieve this appearance if necessary.





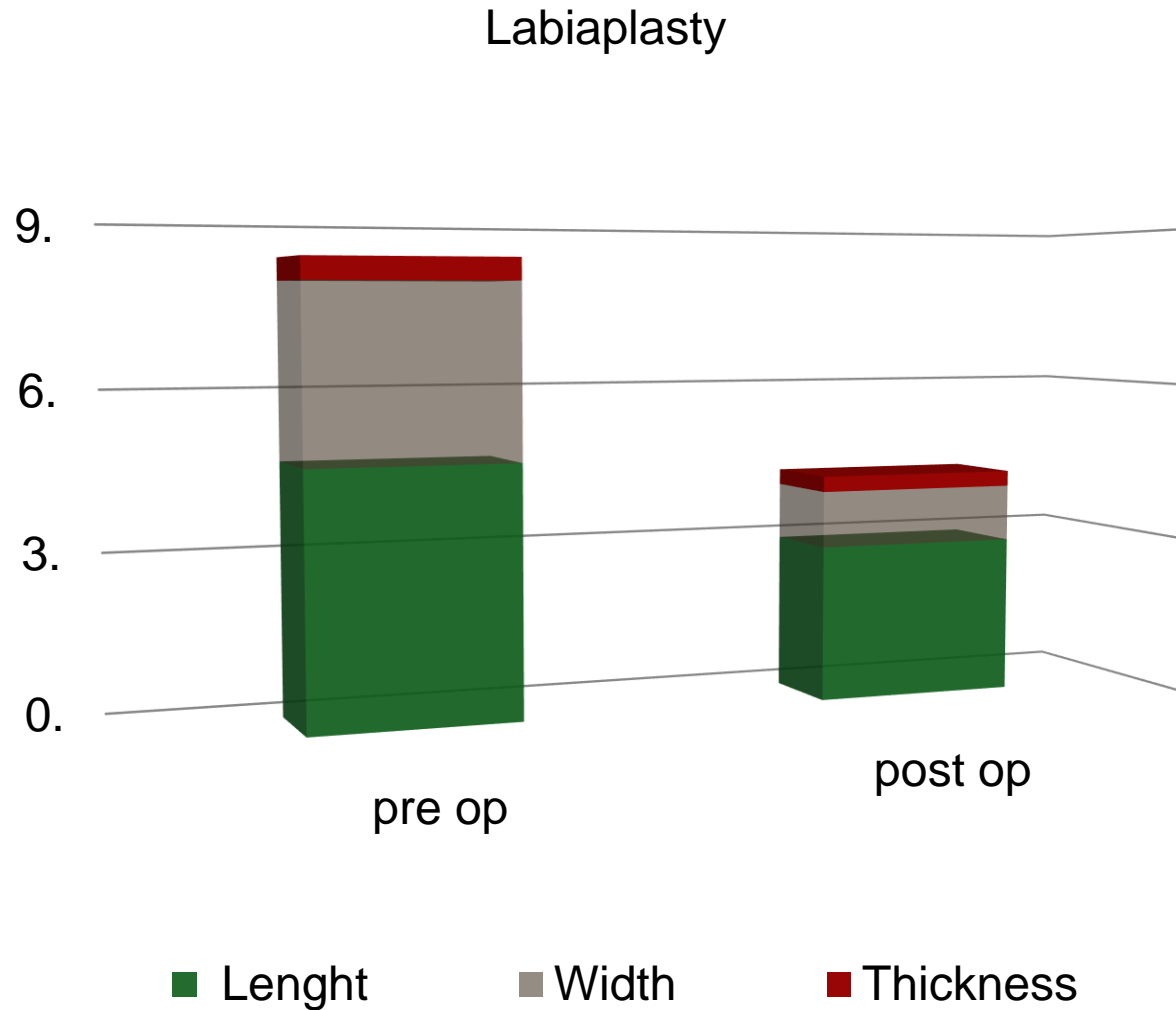
# Results

- Labiaplasty alone was performed in 146 patients
- Labiaplasty + labium majus fat graft filling in 189 patients
- Labiaplasty + clitoral hoodoplasty + labium majus fat graft filling in 65 patients
- Labiaplasty + clitoral hoodoplasty + labium majus fat graft filling + pubis reshaping in 30 patients



# Results

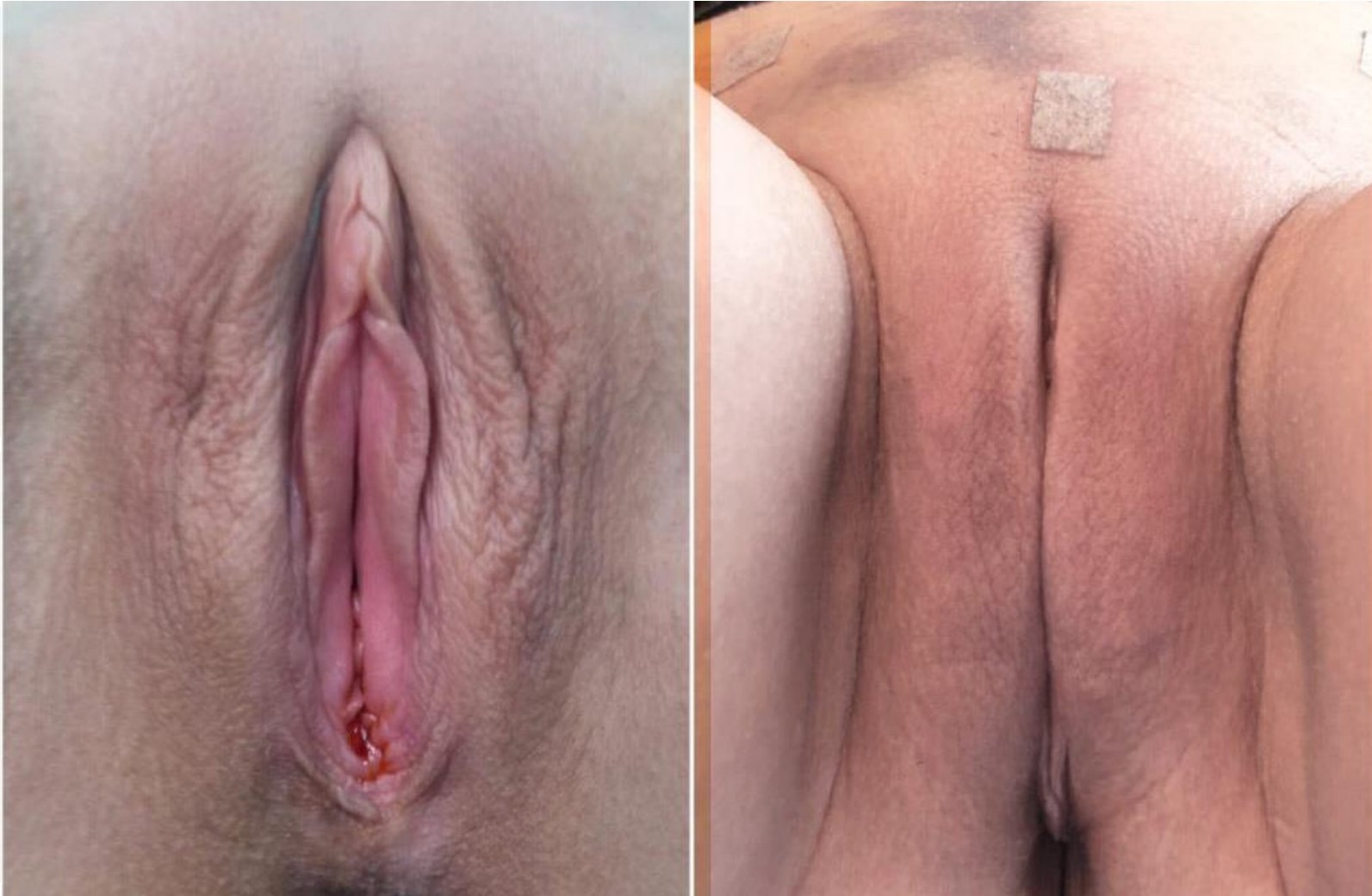The mean preoperative labium minus length was 4.71 cm, width 3.27 cm, and thickness 0.42 cm. After the procedure, the mean length was 2.94 cm, width 1.06 cm and thickness 0.29 cm.



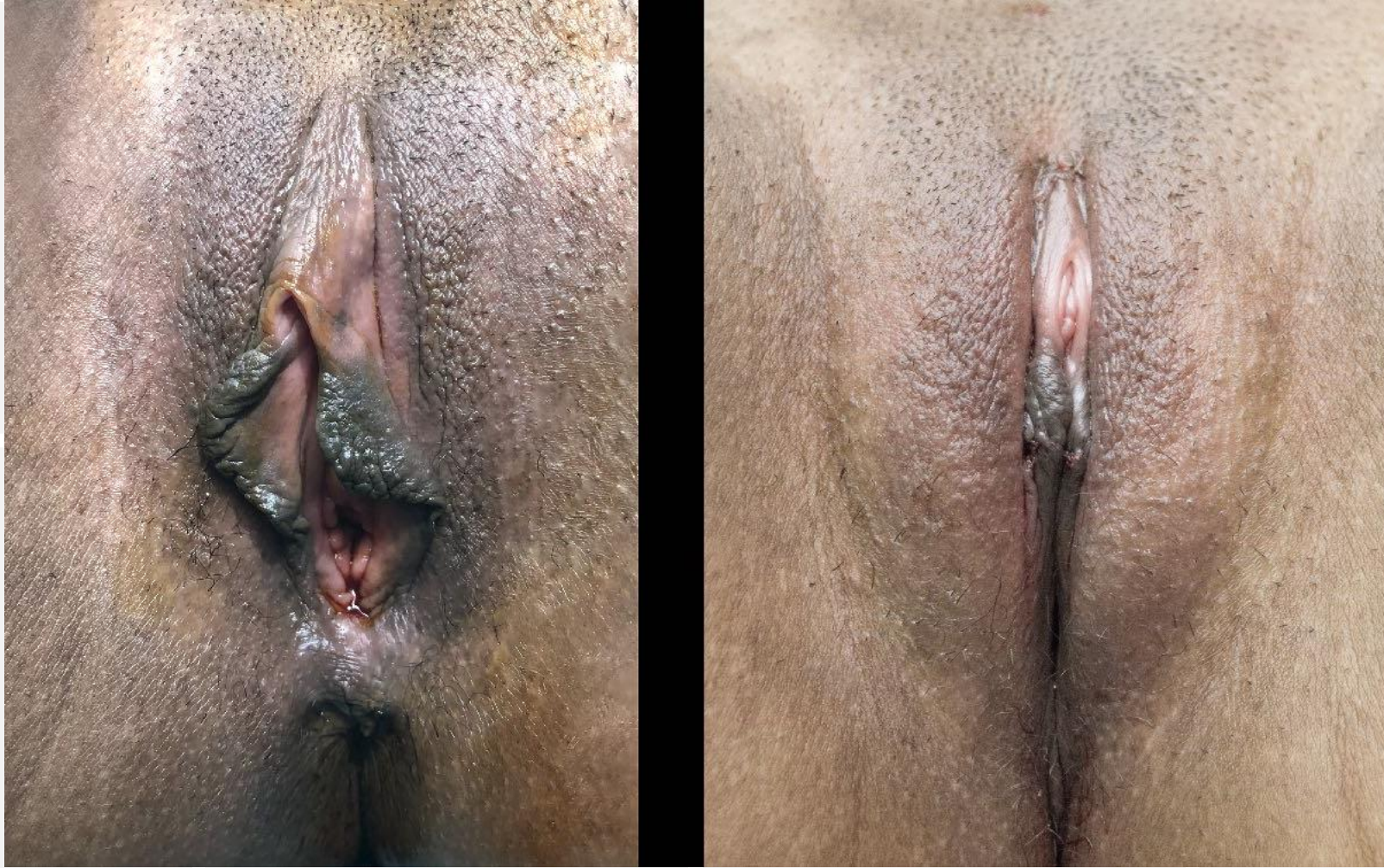
# Results

- The target dimensions for preserving the functionality were defined as: 2.9-3.2 cm for the labium minus length, 0.9-1.1 cm for the width, 0.25-0.3 cm for the thickness
- The ideal appearance in vulva harmonization is when the labium minus and the clitoris do not appear to protrude between the labium majus, both labium majus are close enough to touch each other on the vertical axis, the pudendal cleft is formed, the skin of the labium majus has a tight, smooth appearance without shrinkage, wrinkling

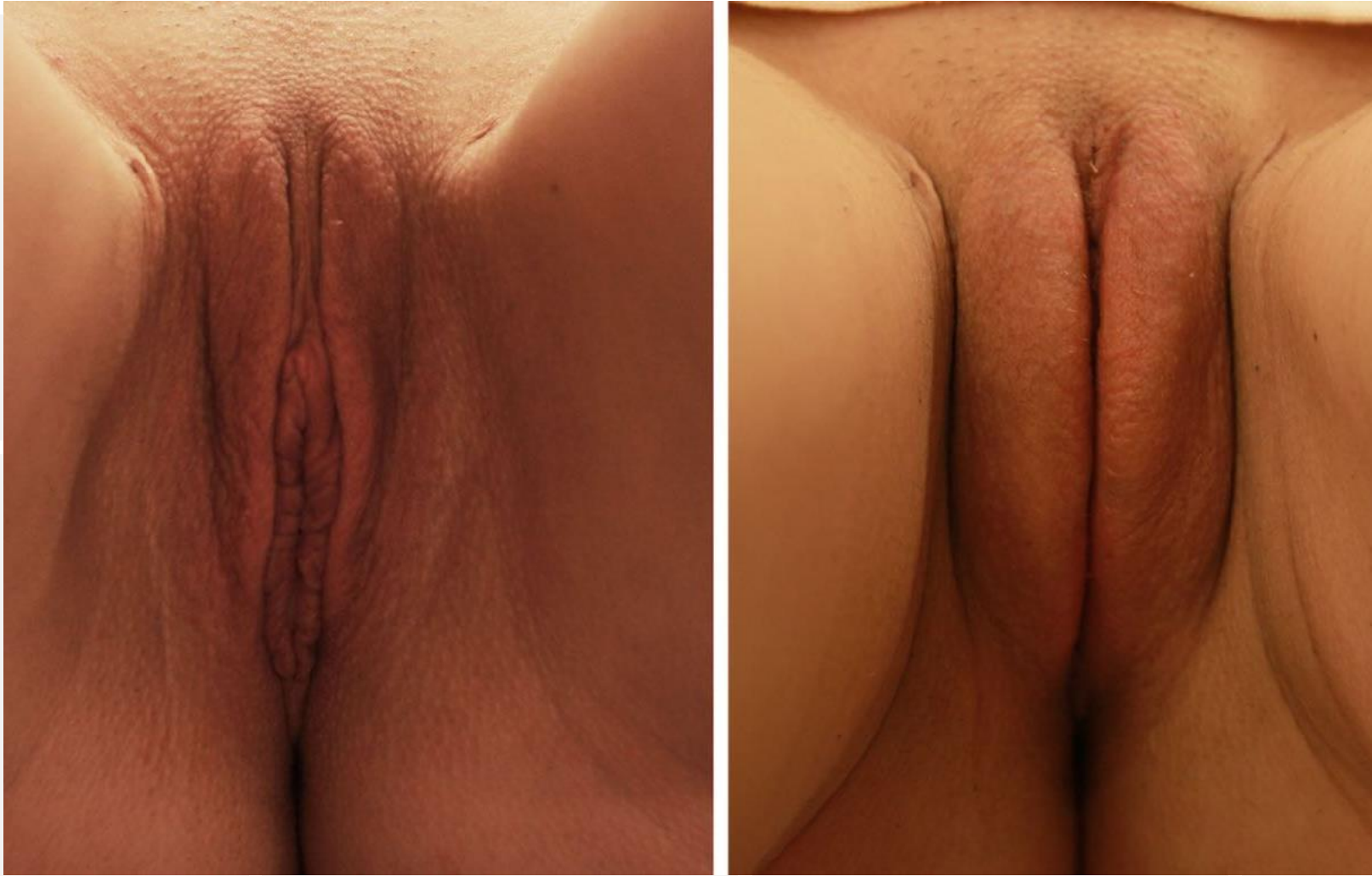



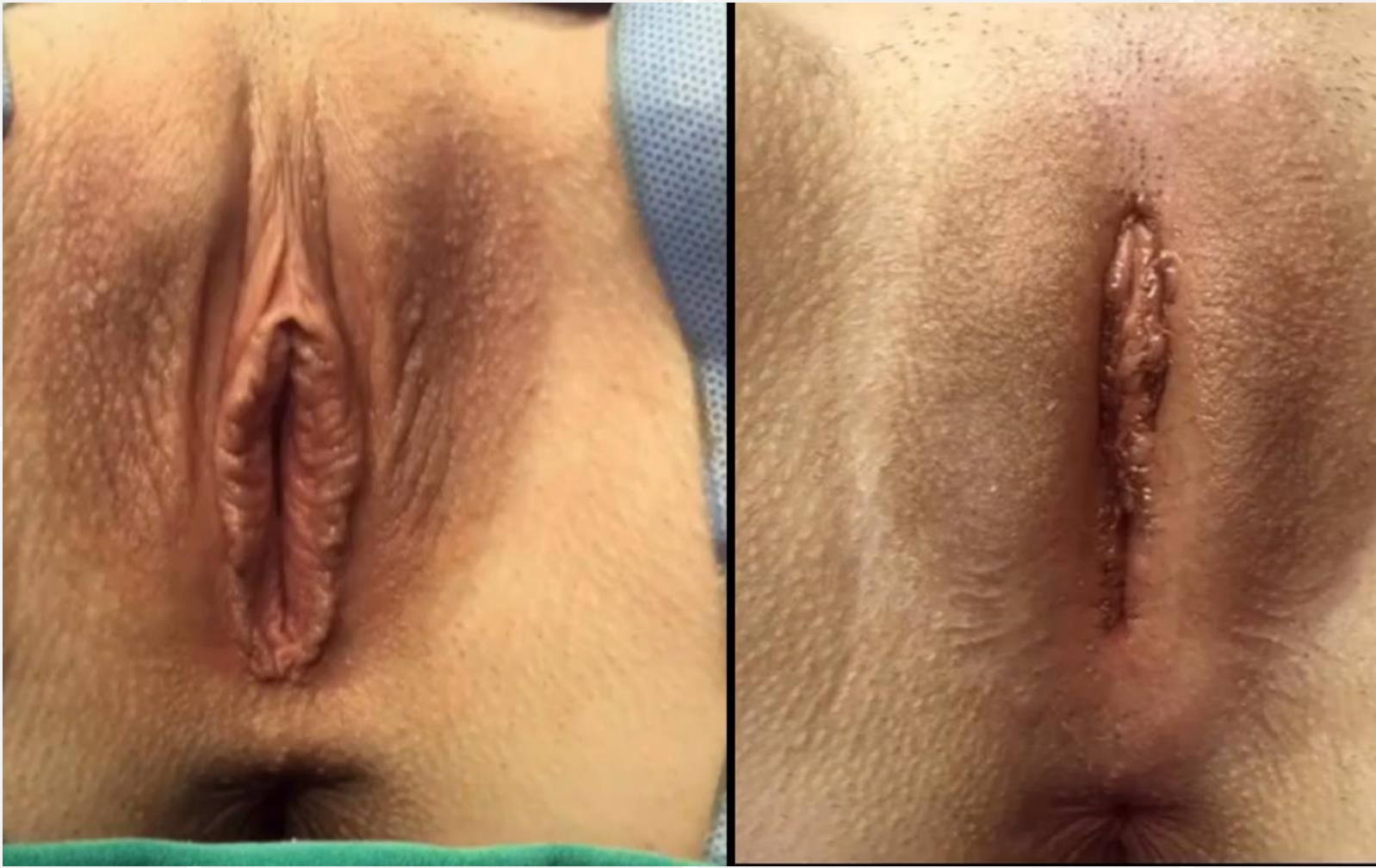**Results**



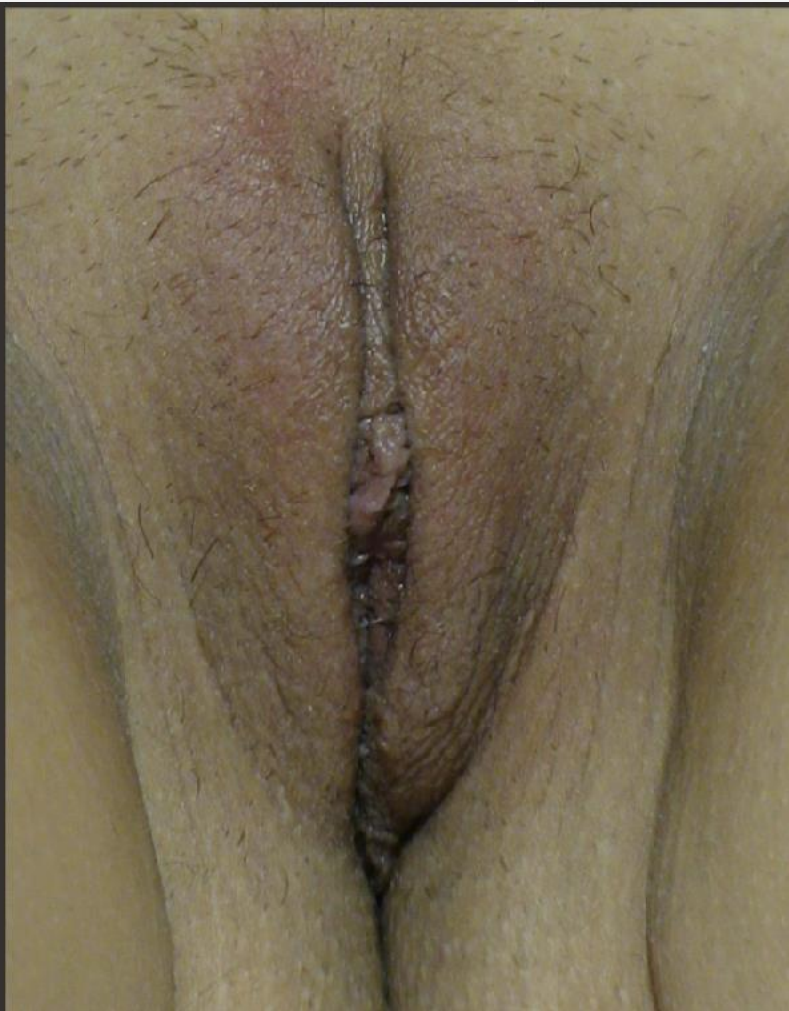**Results**



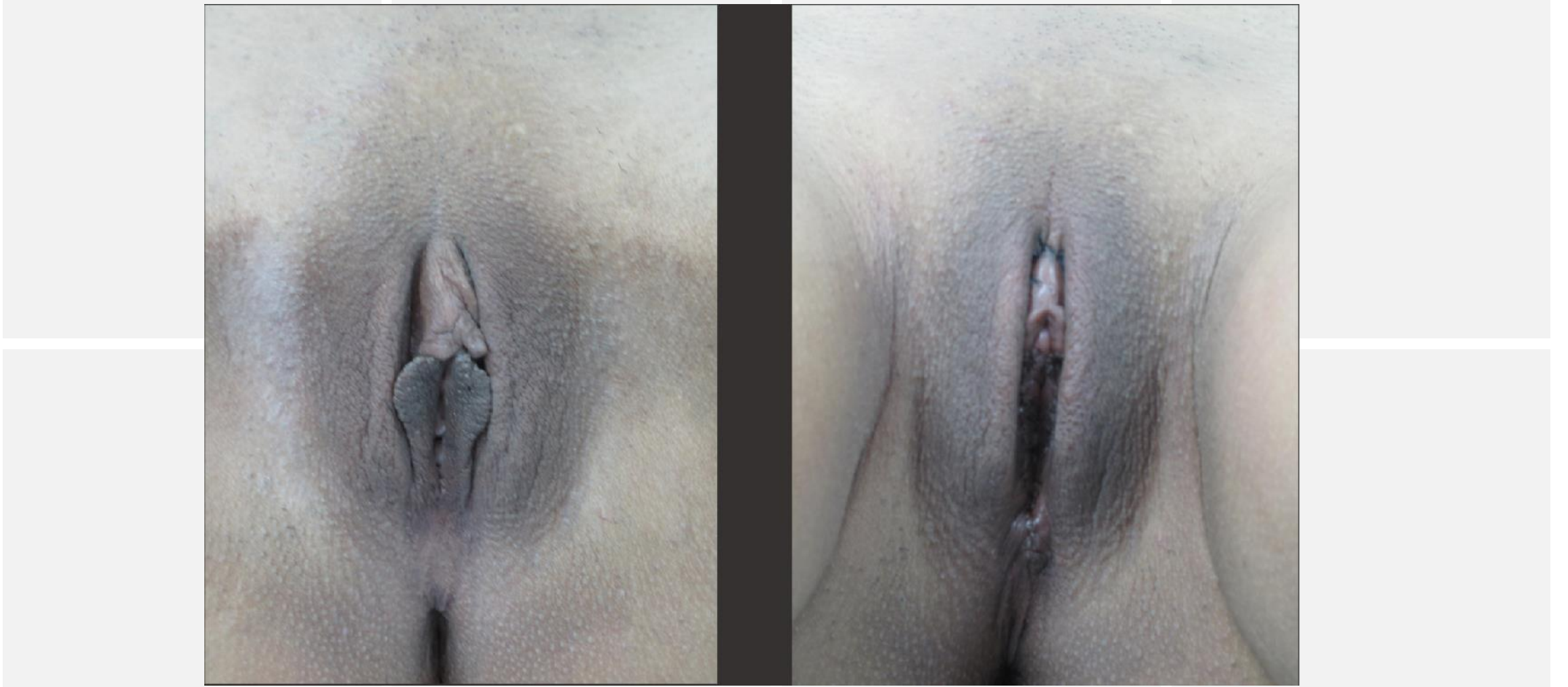
**Results**



**Results**

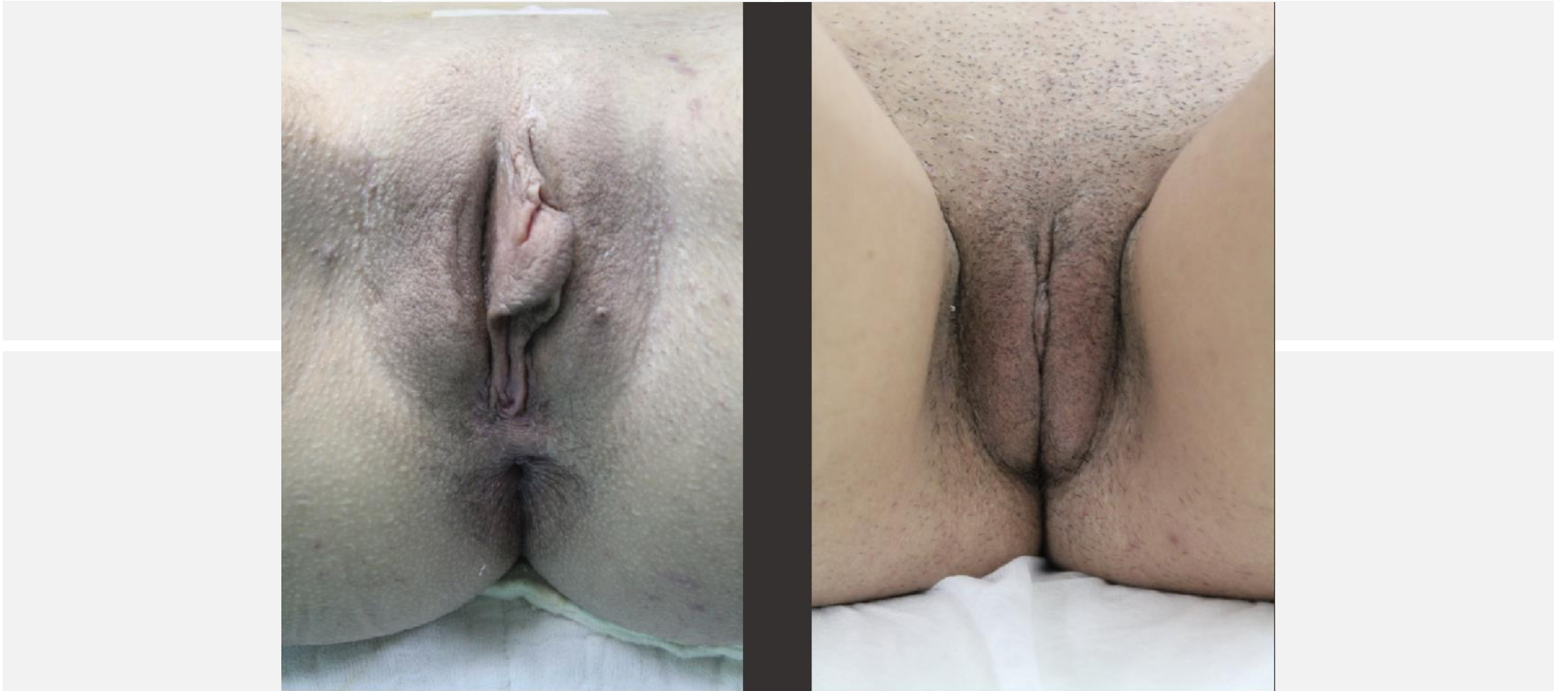


# Results

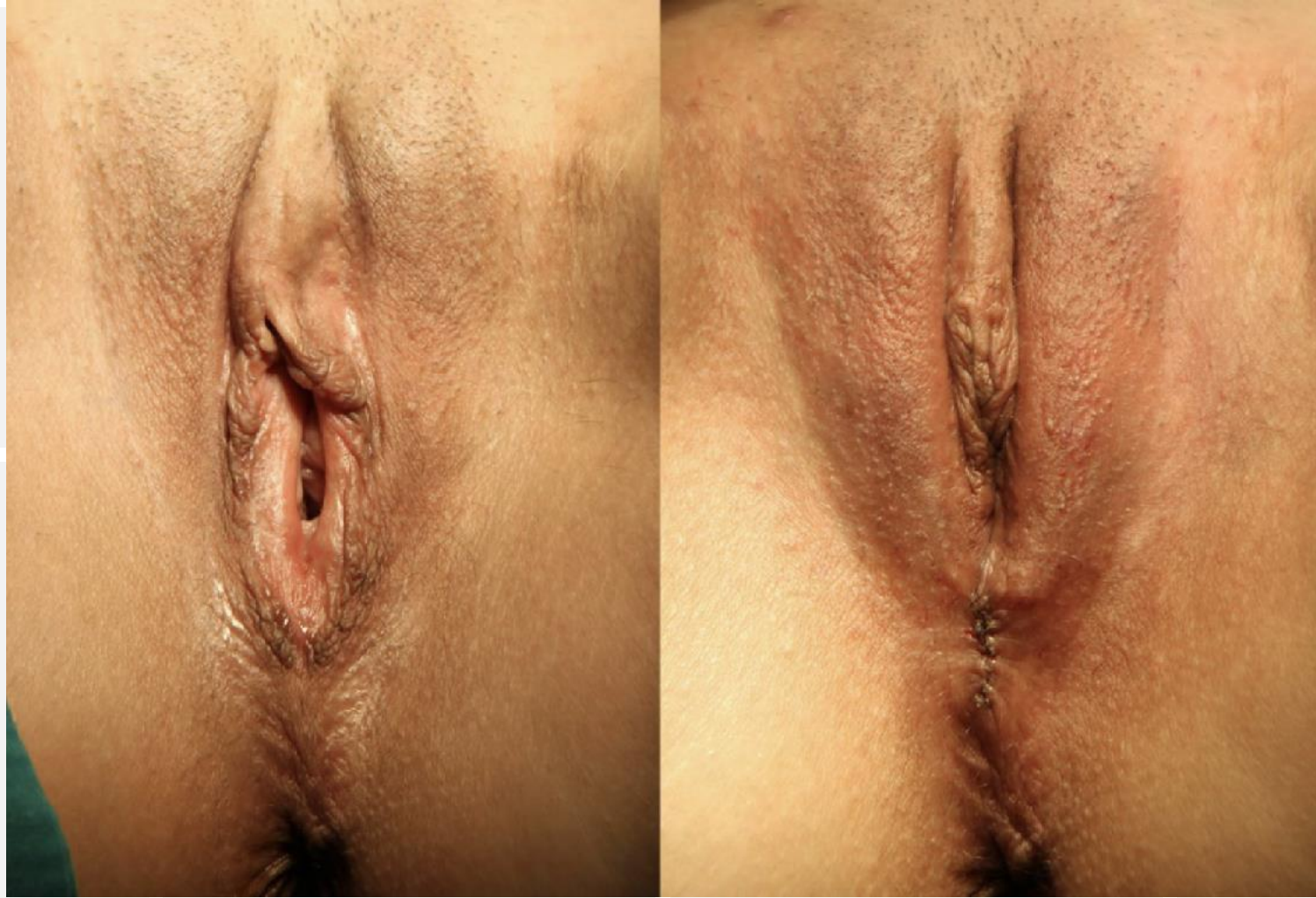

**Results**

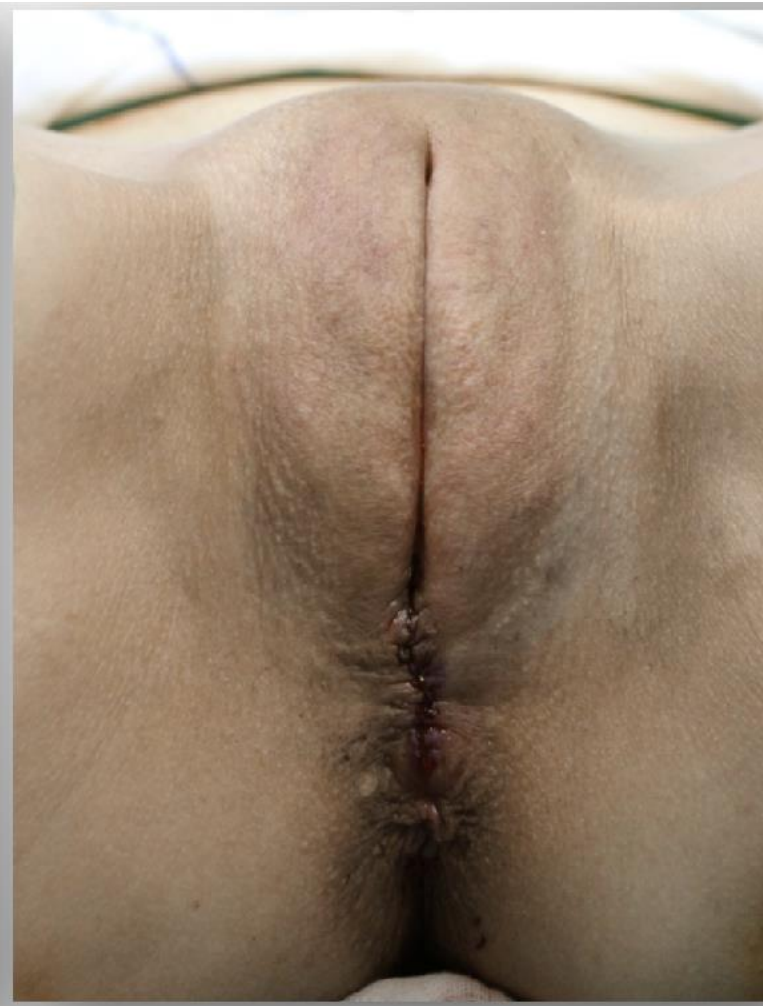
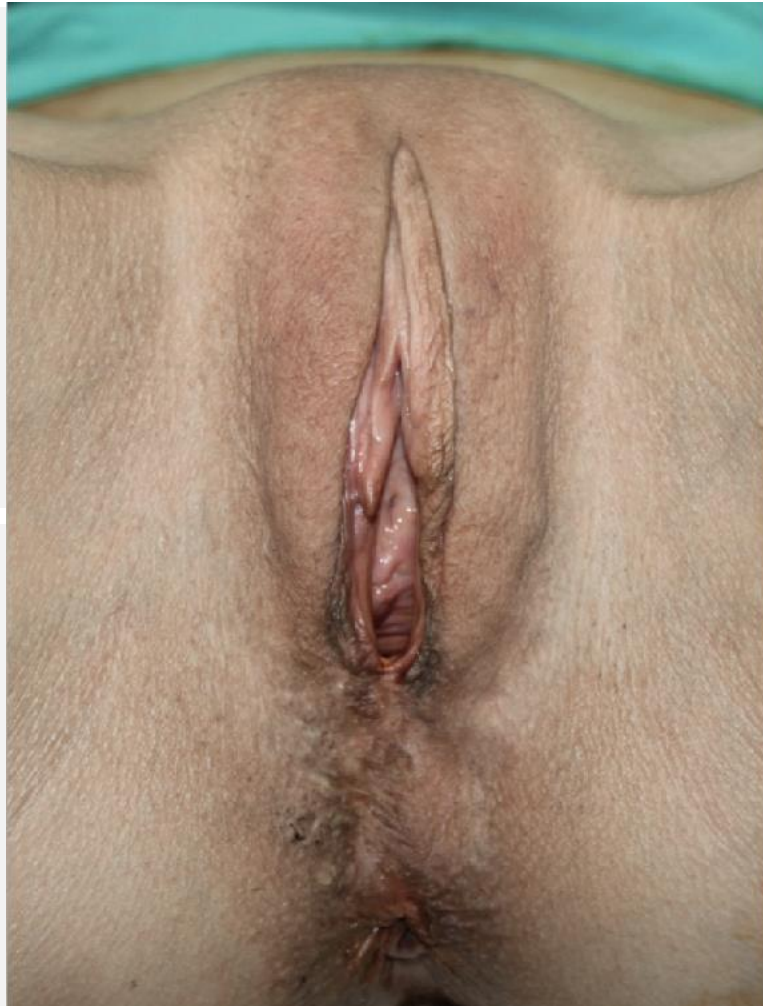


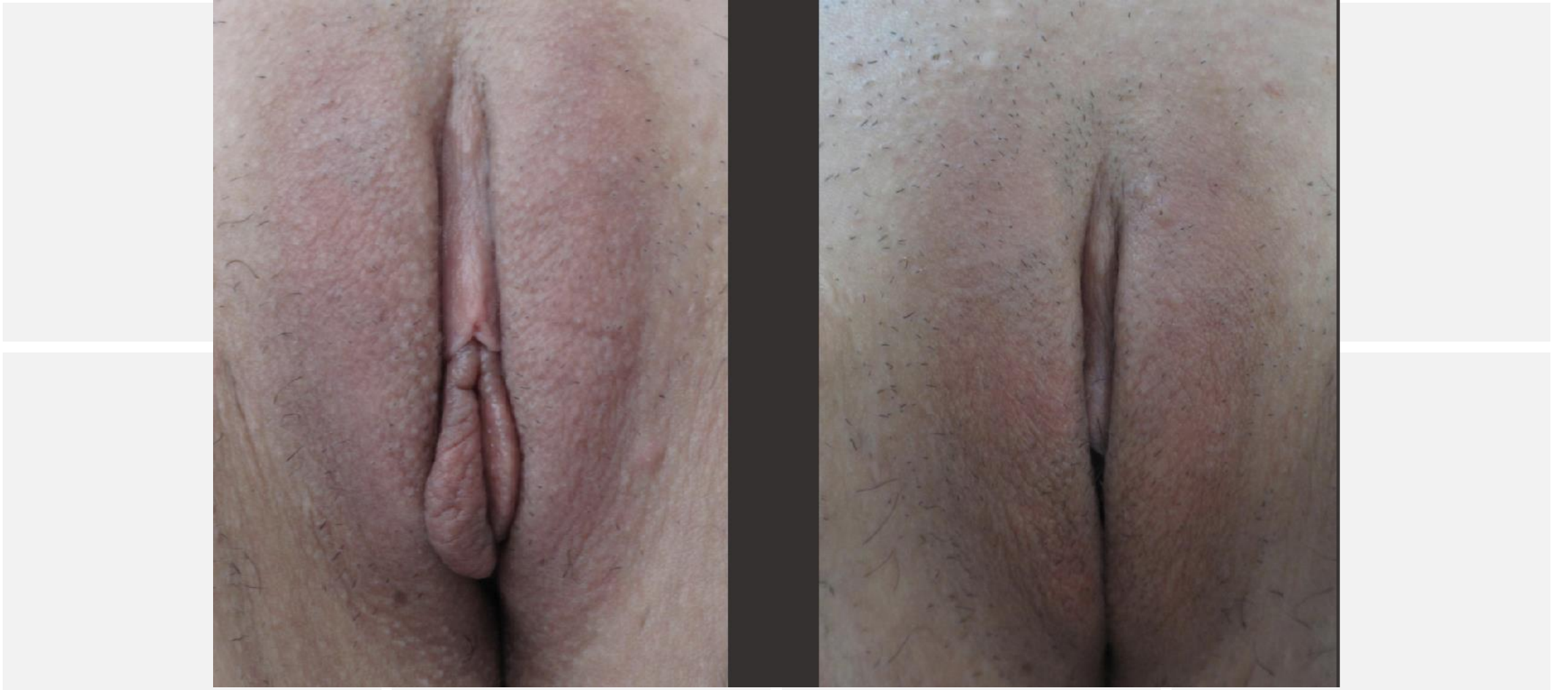**Results**



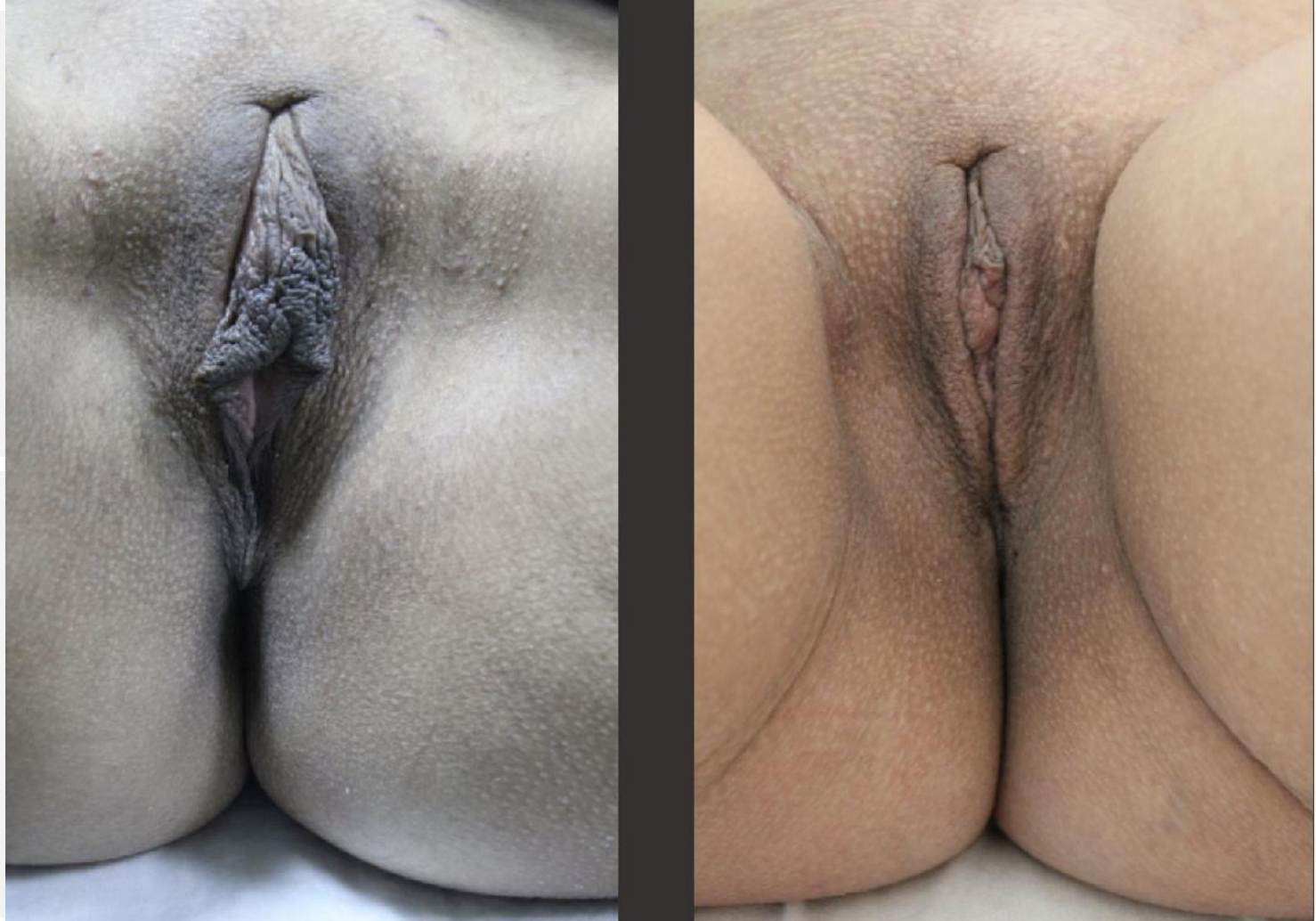
**Results**



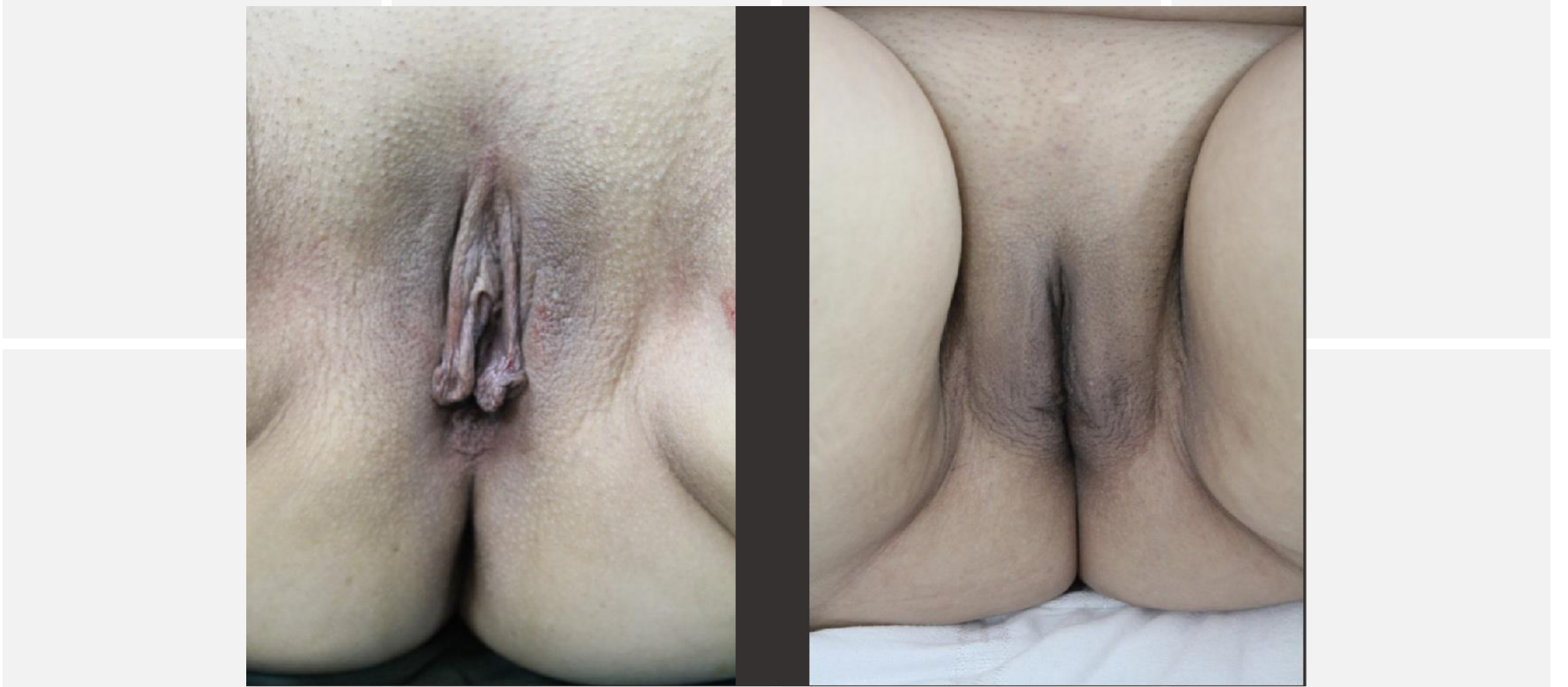**Results**



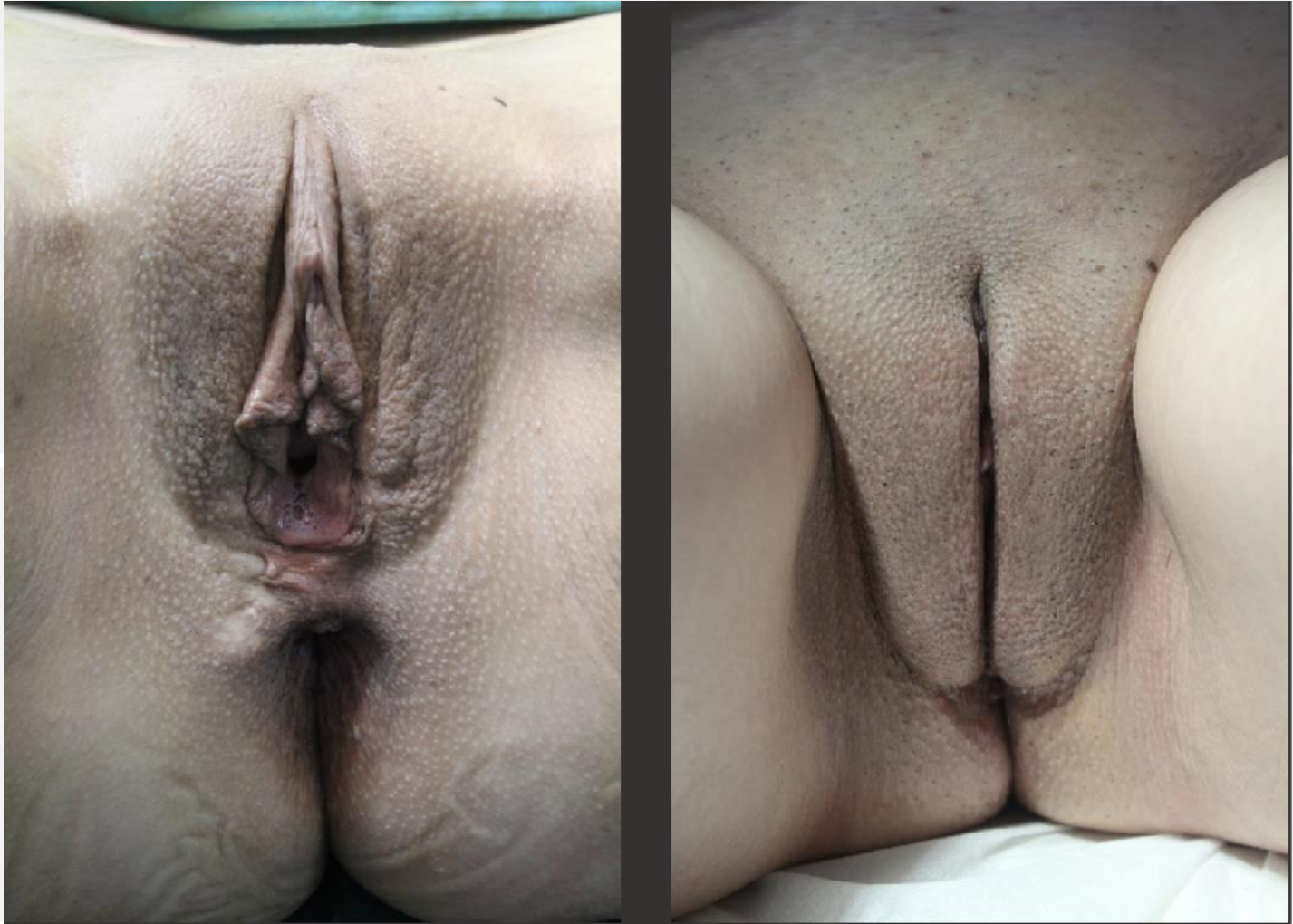**Results**



**Results**



**Results**



**Results**



# CONCLUSION

Defining an ideal vulvar anatomy is a subjective issue given the wide variety of vulvar anatomies. We believe that vulvar harmonization in genital aesthetic operations may provide a reference that can be used by patients and surgeons in pre-surgical planning, increasing surgical success and patient satisfaction rates.

[www.b.doctor](http://www.b.doctor)