

A Case of Recalcitrant Granulomatous Periorificial Dermatitis successfully treated with Isotretinoin

Ji-An UH, Joong-Ho KIM, Ho-Sung Kim,
Soo-Kyung Lee, Myoung-Shin Kim, Un-Ha Lee

Department of dermatology, Sanggye Paik Hospital
Inje University College of Medicine, Seoul, Korea

Case

- **Patient**

- F/32

- **Chief complaint**

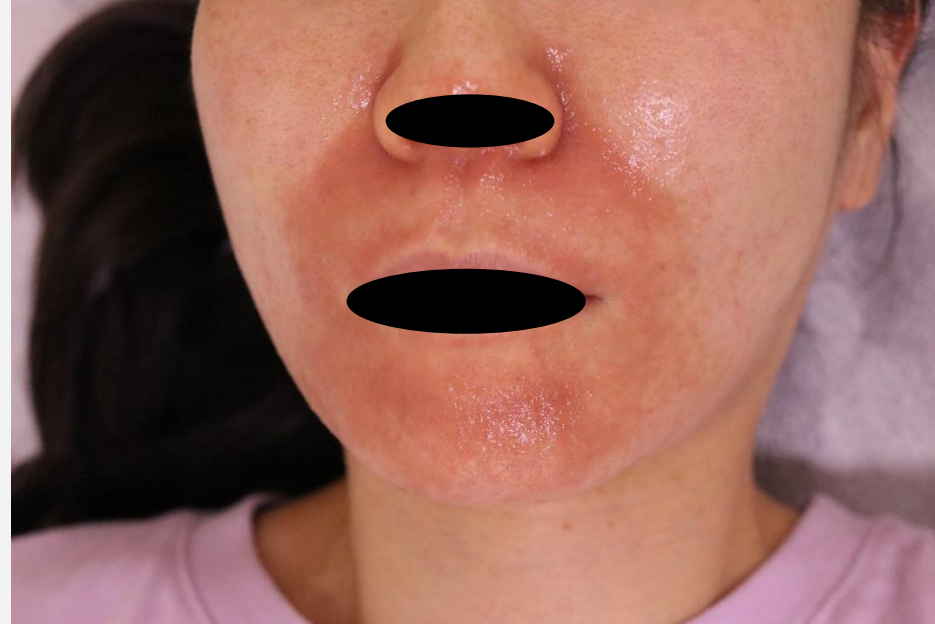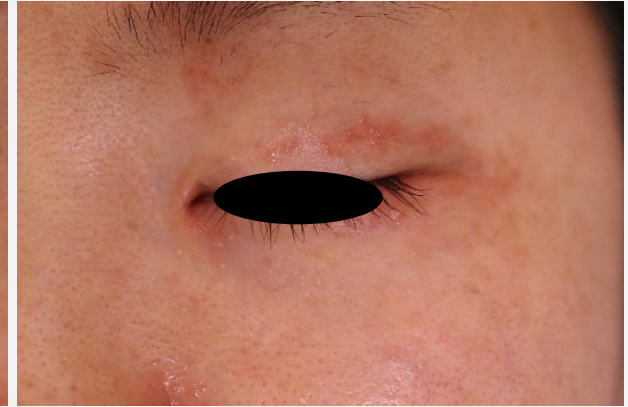
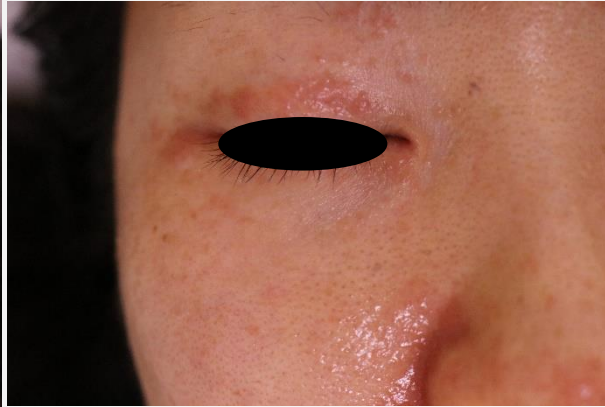
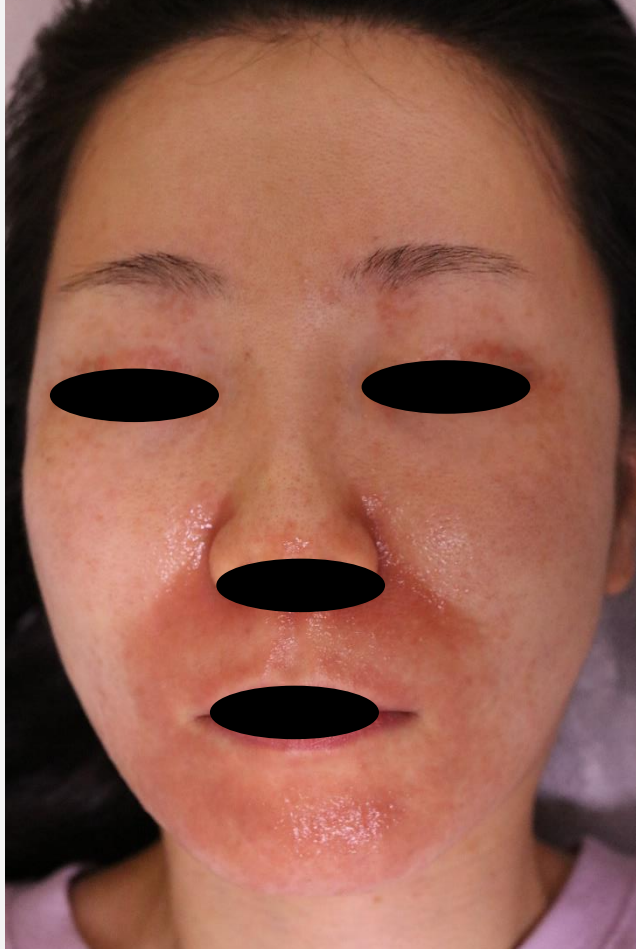- Skin lesion on face
 - Onset : 3 WA

- **Present illness**

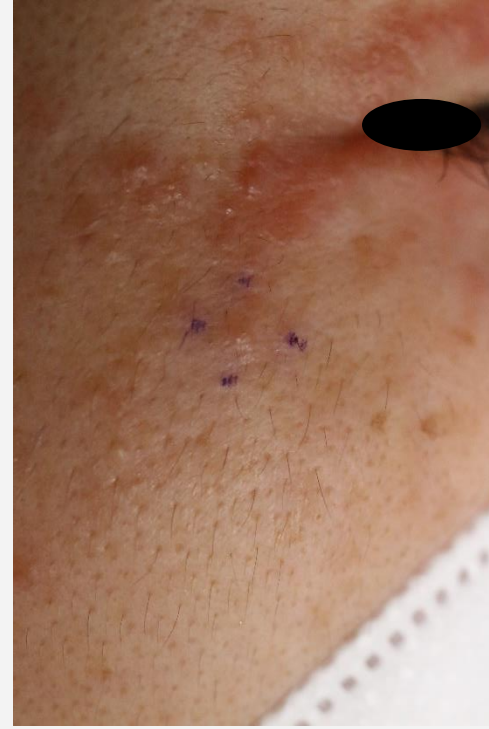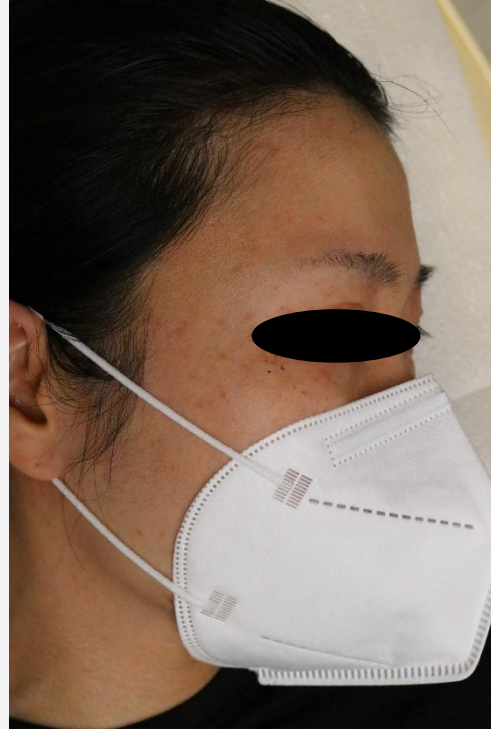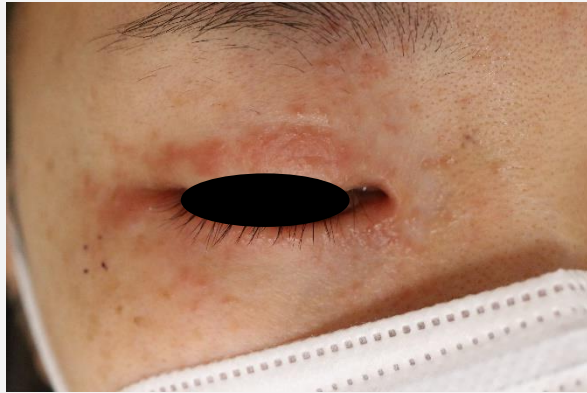
- Erythematous patches with papules (no true pustule)
 - Itching(+), Spreading (perioral area → eyelid)

- **Past History** : n-s

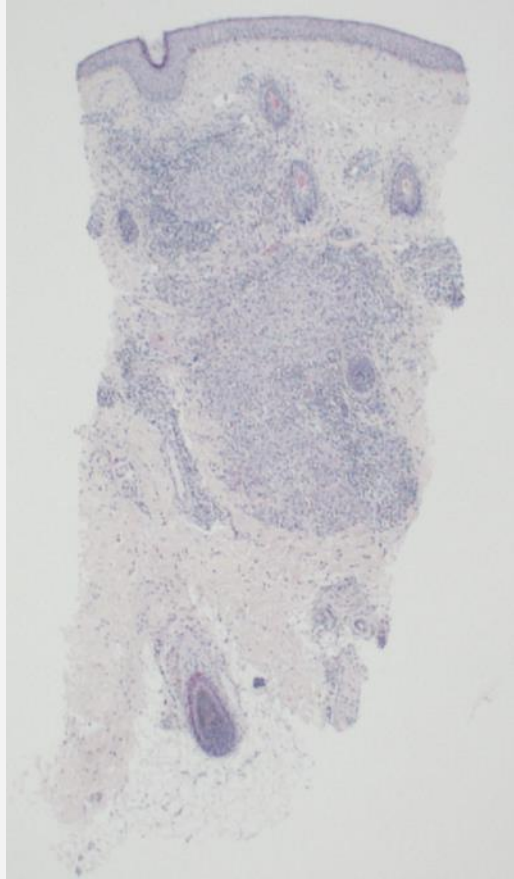
Skin manifestation (2nd VISIT)



Skin manifestation (3rd VISIT)

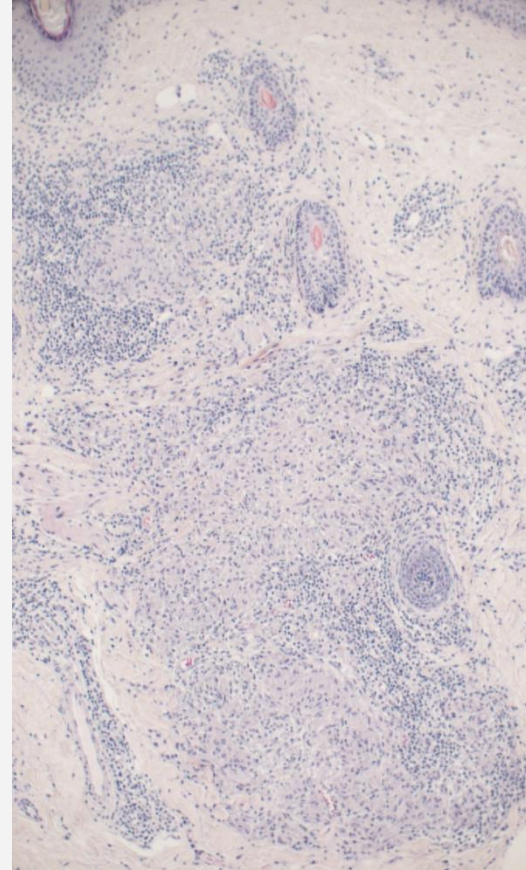


Histopathologic findings

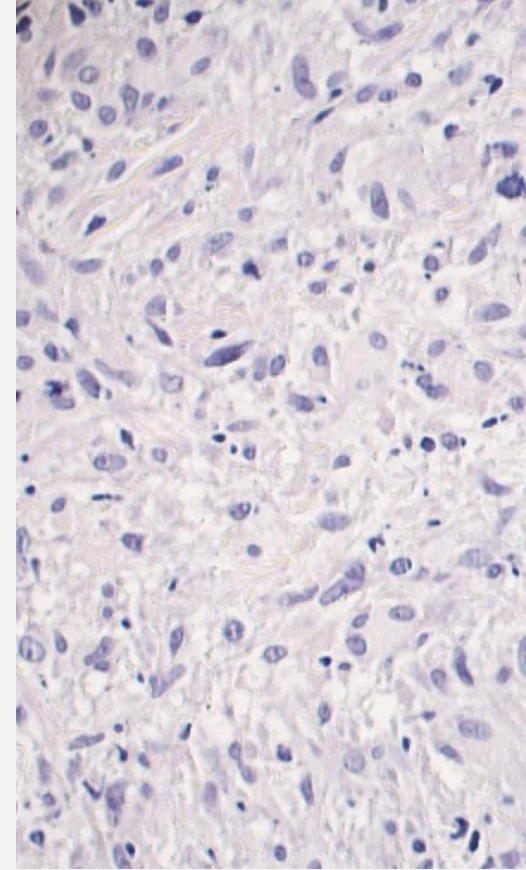


- Granuloma formation in dermis
- Perivascular inflammatory cell infiltration in dermis

(H&E stain, X40)



(H&E stain, X100)



Histiocyte infiltration

(H&E stain, X400)

Histopathologic findings

H & E	Skin, periocular area, right, punch biopsy - Chronic granulomatous inflammation
Special stain	DPAS : negative GRAM : negative AFB : negative

Diagnosis & Management

- **Diagnosis**

Clinical feature & Hx (Periorificial involvement, aggravation after steroid application) + Granuloma

→ Granulomatous periorificial dermatitis

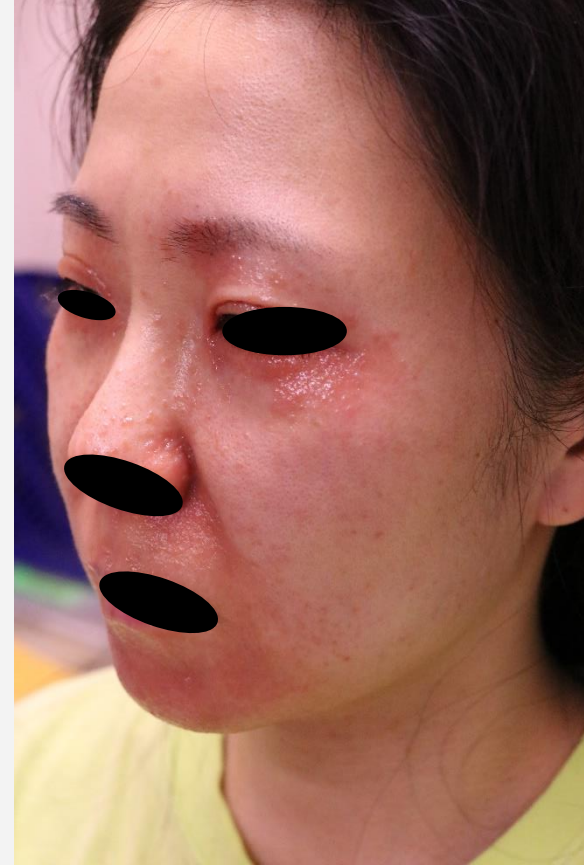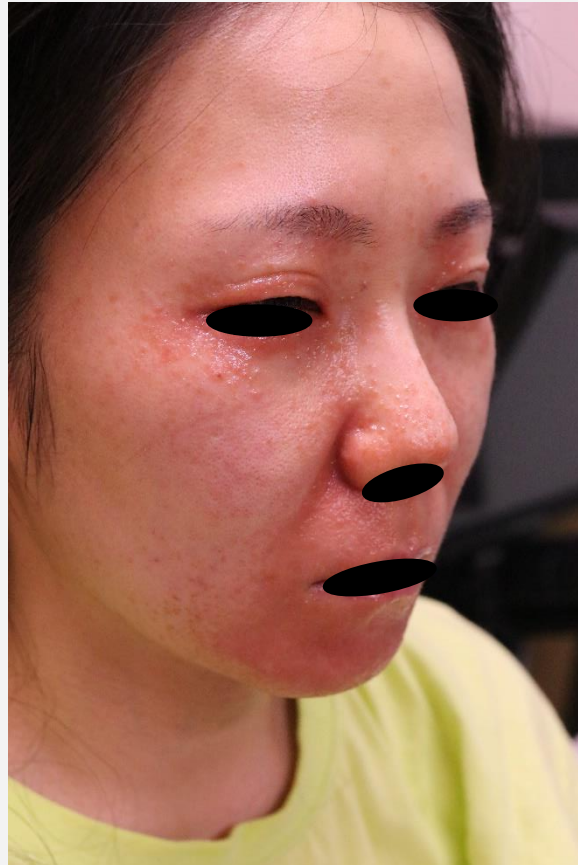
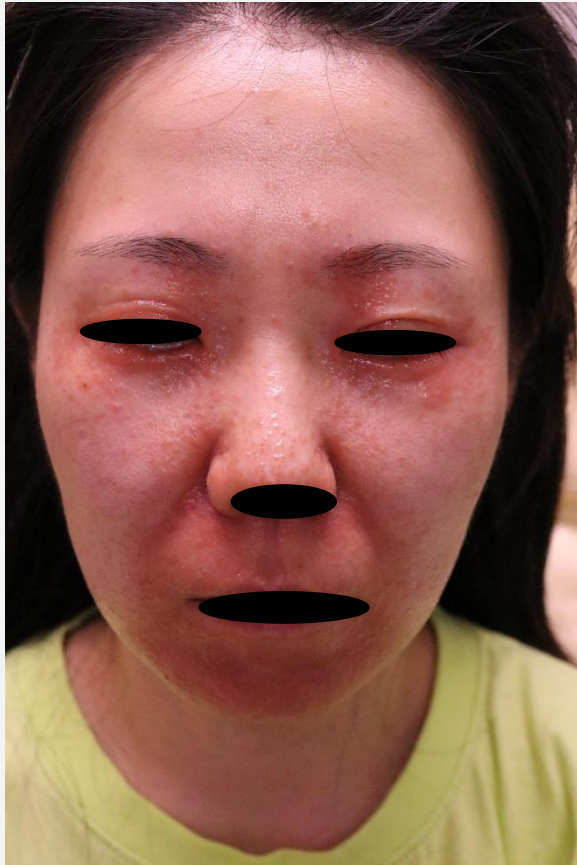
- **Management**

-instruction: not to use topical steroid

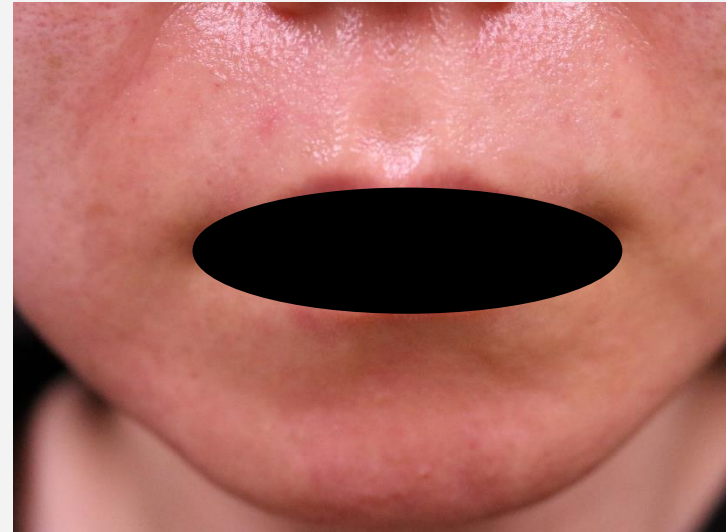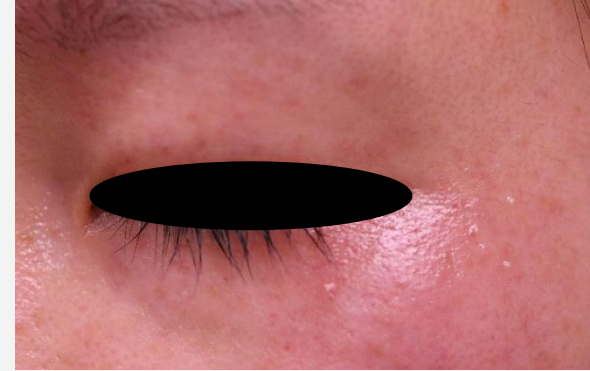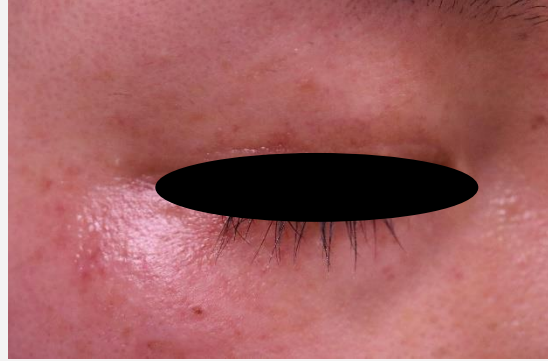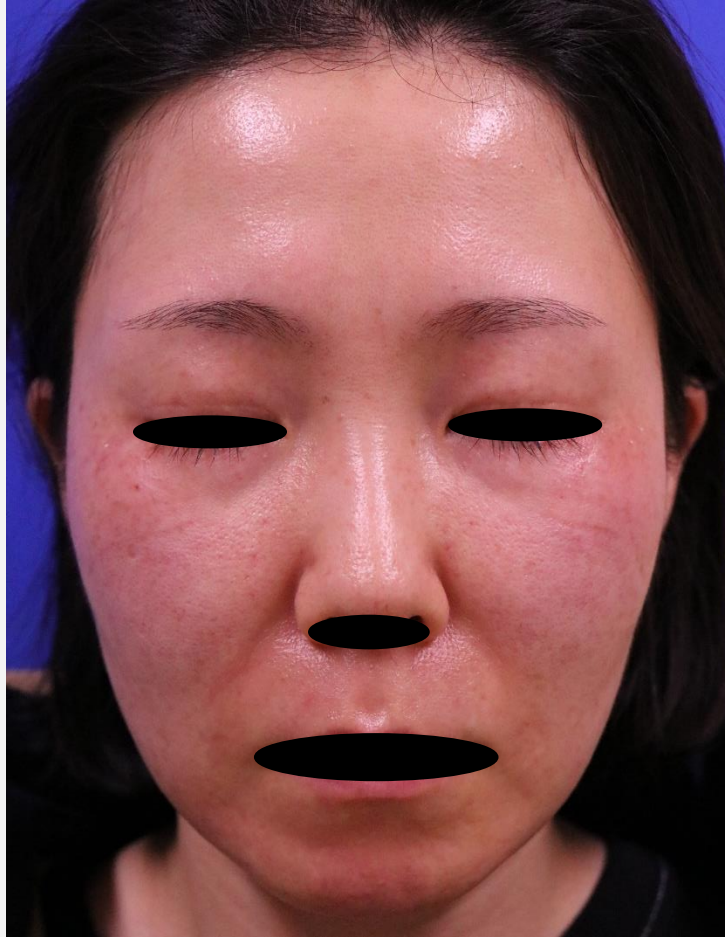-topical calcineurin inhibitor

-po antibiotics (minocyclin) → isotretinoin

Progress (7th VISIT)



Progress (12th VISIT)



Periorificial dermatitis

- **Periorificial dermatitis**

- Group of itchy or tender small red papules
- Occur around the eyes, the nostrils, the mouth, the genitals.
- Predominant in adult women :15 – 45yrs

- **Causes**

- Steroid
 - Topical, Inhaler, oral
- Cosmetics
- Fluorinated toothpaste
- Hygiene
- Hormonal change

Periorificial dermatitis

- **Clinical features**

- Perioral, perinasal, periocular distribution
- Sparing lip border
- Clusters of 1-2mm erythematous papules or papulopustules
- Dry skin
- Itching, Burning sensation

- **Granulomatous periorificial dermatitis**

- Variant of periorificial dermatitis
- Persistent yellowish papules

Periorificial dermatitis

- **Diagnosis**

- Clinical feature

- Skin biopsy

- **Differential diagnosis**

- Granulomatous rosacea

- Fungal or mycobacterial infection

- Familial juvenile systemic granulomatosis (Blau syndrome)

- Sarcoidosis

Treatment

- **General measures**

- Discontinue applying topical steroid
- Avoid occlusive cream, cosmetics

- **Topical**

- Erythromycin, Clindamycin, Metronidazole
- Pimecrolimus
- Secondary bacterial skin infection

- **Oral**

- Tetracycline, Erythromycin (Pregnant, pre-pubertal children)
- Isotretinoin

Conclusion

- Periorificial dermatitis is rare in **Adult**.
- There is no previous domestic report about the treatment response of isotretinoin in Periorificial dermatitis.
- **Isotretinoin can be considered for recalcitrant granulomatous periorificial dermatitis in Adult.**

References

1. Tambe S, Jerajani H, Pund P. Granulomatous Periorificial Dermatitis Effectively Managed with Oral Isotretinoin. *Indian Dermatol Online J.* 2018;9(1):68-70. doi: 10.4103/idoj.IDOJ_129_17.
2. Seong JY, Chae WK, Jung HN, Kong SH, Suh HS, Choi YS. Childhood Granulomatous Periorificial Dermatitis Presented with Erythematous Plaque. *Korean J Dermatol* 2015;53:310-314
3. Rodriguez-Garijo N, Querol-Cisneros E, Tomas-Velazquez A, Estenaga A, Moreno-Artero E, Idoate MA, et al. Recalcitrant granulomatous periorificial dermatitis with good response to low-dose oral isotretinoin. *Pediatr Dermatol.* 2019;36(6):980-981. doi: 10.1111/pde.13969.
4. Kim HK, Kim DH, Park KY, Li K, Seo SJ, Hong CK. Childhood Granulomatous Periorificial Dermatitis Treated with Topical Tacrolimus. *Korean J Dermatol* 2011;49:837-839
5. Teran VA, Belote KG, Cropley TG, Zlotoff BJ, Gru AA. Granulomatous Facial Dermatoses. *Cutis.* 2021;108(4):E5-E10. doi: 10.12788/cutis.0377.
6. Al-Qassabi AM, Al-Busaidi K, Al Baccouche K, Al Ismaili A. Granulomatous Periorificial Dermatitis in an Adult: A case report with review of literature. *Sultan Qaboos Univ Med J.* 2020;20(1):e100-e103. doi: 10.18295/squmj.2020.20.01.015.
7. Smith KW. Perioral dermatitis with histopathologic features of granulomatous rosacea: successful treatment with isotretinoin. *Cutis.* 1990;46:413-415.
8. Lipozencic J, Ljubojevic S. Perioral dermatitis. *Clin Dermatol.* 2014;32:125-130.